

Cerebral oxygenation and the recoverable brain

Richard A. Neubauer and Philip James*

Ocean Hyperbaric Center, Lauderdale by the Sea, FL, USA
*Wolson Hyperbaric Medicine Unit, Ninewells Hospital, Dundee, Scotland, UK

Oxygenation is the most critical function of blood flow and a sudden reduction in oxygen availability is an inevitable consequence of severe ischemic. The resulting cascade of events may result in the failure of membrane integrity of some cells and necrosis, but in the surrounding zone of tissue, less affected by hypoxia, cells survive to form the ischemic penumbra. The timing of these events is uncertain, but sufficient oxygen is available to these cells to maintain membrane ion pump mechanisms, but not enough for them to generate action potentials and therefore function as neurons. The existence of such areas has been suspected for some time based upon the nature of clinical recovery, but has now been demonstrated by SPECT imaging with a high plasma oxygen concentration under hyperbaric conditions as a tracer. A course of hyperbaric oxygen therapy frequently results in a permanent improvement in both flow and metabolism. These changes apparently represent a reversal of the changes that render neurones dormant and the activity of cells, previously undetectable by standard electrophysiological methods, can now be demonstrated. Three patients are presented in whom recoverable brain tissue has been identified using SPECT imaging and increased cerebral oxygenation under hyperbaric conditions. Improved perfusion from reoxygenation has correlated with clinical evidence of benefit especially with continued therapy. [Neurol Res 1998; 20 (Suppl 1): 533-536]

Keywords: Hyperbaric oxygenation; anoxic/ischemic encephalopathy; head injury; stroke; SPECT; revascularisation

INTRODUCTION

Stroke is the third leading cause of death in the United States and a major source of disability. It is not only devastating to the patient and the family, but also creates a large financial drain on resources. In stroke it is often stated that most recovery takes place in the first three months. However, sequential SPECT scanning has indicated that some recovery may take place spontaneously up to six months. Although stroke tissue in the center of the lesion becomes necrotic, in the surrounding zone of tissue, less affected by hypoxia, cells survive to form the ischemic penumbra¹. The timing of these events is uncertain² but sufficient oxygen is available to these cells to maintain membrane ion pump mechanisms, but not enough for them to generate action potentials and therefore function as neurons. The existence of such areas has been suspected for some time based upon the nature of clinical recovery, but has now been demonstrated by SPECT imaging using a high plasma oxygen concentration under hyperbaric conditions³⁻⁵. The use of hyperbaric oxygen therapy has been described in a large series of stroke patients⁶. Another approach to this problem has been the transposition of omental tissue which can revascularise the area to elevate oxygen delivery.

Anoxic ischemic encephalopathy (AIE) with severe hypoxia can affect the brain at any age and may result in necrosis and death, although lesser degrees of hypoxia may not be fatal. Patients may subsequently exist in a locked-in syndrome⁷ or in persistent vegetative coma. Because of the poor prognosis and the high financial costs involved it has actually been suggested that hydration and parenteral nutrition should be withheld in patients in persistent vegetative coma⁸. This condition has many causes, including near drowning, near hanging, CO poisoning, cardiac arrest, electrocution, drug overdose, surgical accidents, anesthetic mishaps and prolonged hypoglycemia. The earlier the onset of hyperbaric oxygen therapy the better the Prognosis¹⁰ and this has been shown by Mathieu et al.⁹ in a series of cases of near hanging. These patients are profoundly oxygen deficient with depletion of ATP and have raised intracranial pressure. Lactic acidosis is also present from anaerobic glycolysis and there are many other biochemical disturbances, including the generation of oxygen free radical species, which are damaging to neurons. This phase gains momentum at about 30 min and evolves over several hours, depending upon the severity of the hypoxia. It has often been stated that patients with a Glasgow Coma Scale score of less than six have little chance of recovery after three months in coma and spontaneous recovery after prolonged coma merits extensive media coverage. However many such cases are on record with intervals of several years. Clearly, it is

Correspondence and reprint requests to: Richard A. Neubauer, Ocean Hyperbaric Center, 4001 Ocean Drive, Lauderdale by the Sea, FL 33308, USA. Accepted for publication November 1997.

of the greatest importance to be able to identify such patients and the best methods of intervention. It is also critically important to recognise that the electrophysiological tests in current use may be misleading, because they cannot identify viable tissue in the ischemic penumbra.

Of relevance both to recovery after stroke and anoxic-ischemic encephalopathy, is recent research which has identified stem (progenitor) cells in the adult mammalian brain². This points to greater powers of recovery than has been thought possible and embryonal implants have also been under investigation. Remyelination has also been described experimentally¹³. The basic requirement to underpin all of these developments is an adequate microcirculation and the transport of sufficient oxygen. Most forms of brain insult also cause damage to the microcirculation and the critical factor in recovery is the tissue oxygen tension which, at a given plasma oxygen tension, is a function of the diffusional distance. This is increased by the presence of edema, which MRI has shown is a chronic feature of brain injury. A mild degree of hypoxia is a stimulus to neogenesis, but clearly a severe degree of oxygen depletion prevents all cellular activity. The value of serial hyperbaric oxygen therapy in revascularisation has been well-established in skin and bone and it is anticipated that this effect will be confirmed in the brain in man.

PATIENTS AND METHODS

Three patients with brain injury were studied after hypoglycemic coma, stroke and near drowning respectively. An initial SPECT scan was undertaken in the three patients followed by sessions in a monoplace hyperbaric chamber at 1.5 atm abs (Vickers Ltd, Hampshire, UK). The radioactive tracer used was Tc 99m HMPAO (Ceretek, Arlington Heights, IL, USA) with the dose adjusted to the patient's weight. Scanning was undertaken with a single head gamma camera (Elscint SP 6, Elscint Inc., Hackensack, NJ, USA). Sequential scanning was undertaken either after the first session or after a course of therapy of 1-2 sessions daily five days a week, up to a maximum of 154 sessions.

Case reports

Case PR (Figure 1)

A 74 year old white male patient experienced the acute onset of right-sided weakness, dizziness and slight confusion. Within 3 h of the onset, the patient had a SPECT scan with a split dose of Technetium 99m HMPAO. A quarter dose was administered for the first scan and the patient was then given oxygen in a hyperbaric chamber at 1.5 atm abs for 1 h. The remaining three-quarter dose of Tc 99m HMPAO was administered and scan was repeated after 2h. The original scan showed a marked reduction of perfusion in the territory of the left middle cerebral artery. There was reduced perfusion in the left temporal lobe of the basal

ganglia, the posterior occipital poles and throughout the lower gyre of the frontal lobes, again worse on the left. The follow-up scan after hyperbaric oxygen and the remaining three-quarter dose showed a marked improvement in perfusion and metabolism of the left mid-cerebral artery. A repeat scan performed after 6 weeks following a total of 16 hyperbaric treatments, but one and a half months after final treatment, showed a holding pattern with even further overall improvement. No neurologic deficits were noted. It must be noted that because the symptoms may have resolved within 24 h this could be classified as a transient ischemic attack. However the use of a split dose of Tc 99m HMPAO SPECT with hyperbaric oxygenation made it possible in this case to make rational prediction of the extent of his final recovery. The patient was therefore treated at home with physical therapy as well as HBOT. If such a treatment were established for patients during the transient ischemic attack, or as an effective modality in stroke, hospitalization may be avoided, the outcome significantly improved and costs dramatically reduced.

Case AS (Figure 2)

This patient was a 14 year old diabetic girl with an encephalopathy resulting from severe hypoglycemia and prolonged seizures 6 months previously. The patient had been diagnosed with labile juvenile diabetes at age 5, and had experienced multiple episodes of hypoglycemia. At the time of the last incident, she was found convulsing and was unresponsive to two injections of Glucagon. The seizure became continuous and she was hospitalized and intubated in the ICU. She was in coma for about 1 week and when seen had begun walking but her speech was poor. She was agitated and combative with violent rages. She had no use of her left hand and could not grasp with her right. Baseline SPECT showed a 'diffuse cerebral deficit pattern consistent with a severe hypoxic effect'. Following 88 hyperbaric oxygen sessions a repeat scan showed 'diffusely improved cerebral perfusion'. After treatment it was obvious that this patient had made significant progress. She is now calm, gets on the schoolbus herself daily and attends a special school.

Case EC (Figure 3)

A 22 year old boy was seen 1 1/2 months after a near-drowning episode. The child hit his head and fell into the swimming pool. It is not known how long he was submerged. The family was told that the child was blind and he presented in a persistent vegetative state with severe spasticity on the left side and hypomobility of the right leg. He was fed by PEG tube. Initial SPECT imaging showed extensive and symmetrical deficit throughout frontal, temporal, parietal and occipital lobes. After three treatments with hyperbaric oxygen therapy the patient began moving more, trying to speak, and 'acting up' when angry. The patient began crying with tears for the first time after 16 treatments. After 26 treatments the

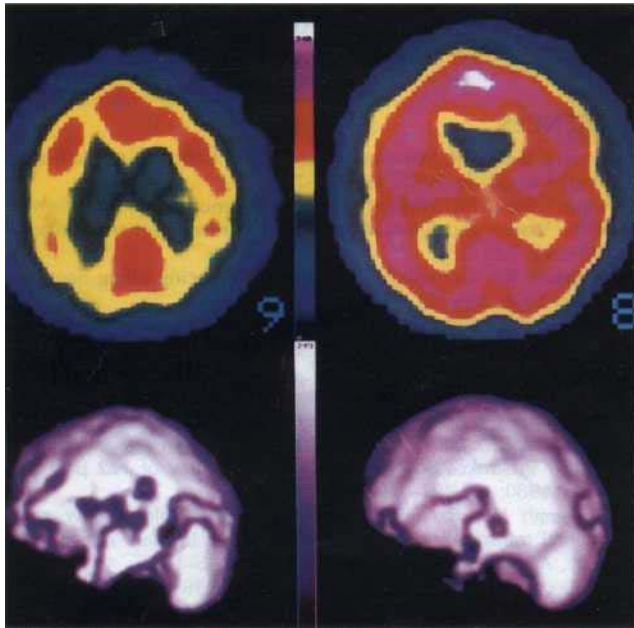


Figure 1: Case PR pre- and post-16 HBO treatments. Axial and 3D cortical reconstruction

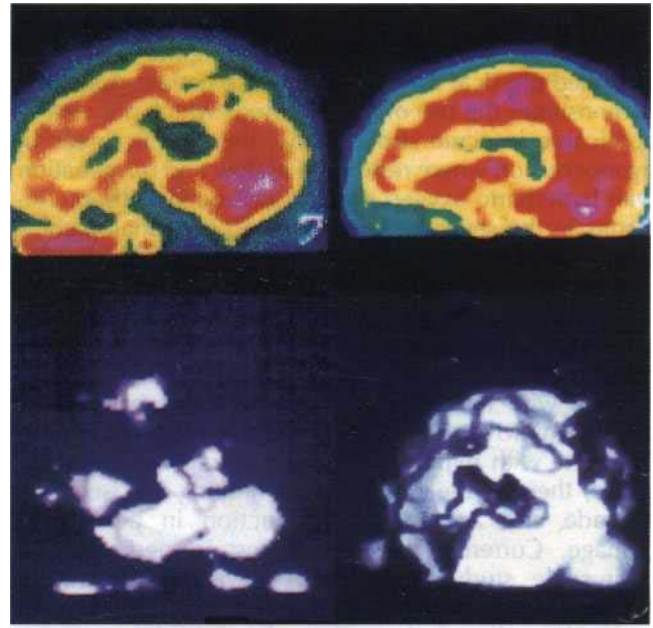


Figure 2: Case AS pre- and post-88 HBO treatments. Sagittal and 3D cortical reconstruction

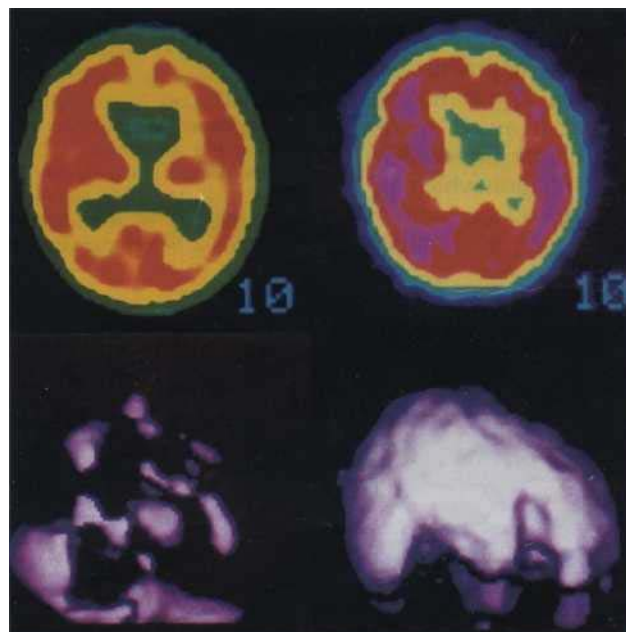


Figure 3: Case EC pre- and post-120 HBO treatments. Axial and 3D reconstruction

patient was smiling, much more alert, laughing, crying, sleeping much better and laughing while dreaming. Following 34 treatments the patient was more aware, developing much more eye contact and was clearly not blind. To date the patient has received 154 treatments and now sees clearly, is speaking bi-lingually, standing and taking a few steps. He is now able to eat and drink normally.

DISCUSSION

These patients represent two separate categories for the use of hyperbaric oxygen therapy in increasing cerebral oxygenation, in acute and chronic states. The treatment of stroke with hyperbaric oxygenation at relatively low hyperbaric pressures was published in 1980⁶ where it was shown that although early intervention would not necessarily reduce the mortality rate, it would signifi-

cantly reduce the day hospitalization as well as, in other cases, abort the need for nursing home care and extended physical therapy. The stroke patient described demonstrates the use of new methods which are clearly applicable in acute stroke. Now, the specific areas of hypoperfusion where restitution of flow and oxygenation with hyperbaric oxygen therapy, can be visualised. The results in the severe anoxic/ischemic encephalopathies clearly indicate that hyperbaric oxygen should be the primary therapy with a large percentage of patients improving from PVS to an awareness and in some cases the patients can re-enter society. There was a direct relationship between the use of hyperbaric oxygen therapy with the improved cerebral oxygenation and clinical improvement in all cases. If it were possible to intervene with hyperbaric oxygen therapy in the acute phase, there is the possibility of limiting the ischemic cascade and a significant reduction in permanent damage. Currently there is interest in performing a large-scale study in the USA of acute hyperbaric oxygenation, that is within the first three hours, with and without thrombolysis. Traumatic head injury is also associated with edema and perfusion deficits and the methods described in this paper have also been used in the therapy of such patients in coma and with neurological deficits^{5,14}.

It is important for any treatment to be combined with physical therapy, rehabilitation programmes and vocational training to help redirect recovering neural tissues. Training in tasks requiring manual skills, also stimulates blood flow. It is also suggested that it assists in re-establishing neural networks, in particular the cortical areas involved in integration and coordination which aid in the reorganization of undamaged parts of the brain. It is hoped that discussion of these cases will stimulate

interest in this rewarding area of research and add to our knowledge of the ischemic penumbra.

REFERENCES

- 1 Astrup J, Siesjo BK, Symon L. Thresholds of ischemia; the ischemic penumbra. *Stroke* 1981; 12: 723-725
- 2 Astrup J, Siesjo BK, Symon L. The state of penumbra in the ischemic brain: Viable and lethal threshold in cerebral ischemia. *Stroke* 1981; 12: 723-725
- 3 Neubauer RA, Gottlieb SF, Kagan RL. Enhancing idling neurons. *Lancet* 1990; 335: 542
- 4 Neubauer RA, Gottlieb SF, Miale A Jr. Identification of hypometabolic areas in the brain using brain imaging and hyperbaric oxygen. *Clin Nucl Med* 1992; 17: 477-479
- 5 Neubauer RA, Gottlieb SF, Pevsner H. Hyperbaric oxygen for treatment of closed head injury. *Southern Med J* 1994; 87: 933-936
- 6 Neubauer RA, End E. Hyperbaric oxygenation as an adjunct therapy in strokes due to thrombosis. A review of 122 patients. *Stroke* 1980; 11: 297-300
- 7 Goldsmith HS, Bacciu P. Regional cerebral blood flow after omental transposition to the ischemic brain in man. A five year study. *Acta Neurochir (Wien)* 1990; 106: 145-152
- 8 The persistence of mind. Editorial. *Lancet* 1996; 348: 69
- 9 Zaman A. Persistent vegetative state. *Lancet* 1997; 350: 795-797
- 10 Yu Li-hua, et al. The experience of HBO therapy for resuscitation of heart, lung, and brain. *Chinese J Hyperbaric Med* 1983; 3: 6-9
- 11 Mathieu D, Wattel F, Gosselin B, et al. Hyperbaric oxygen in the treatment of posthypoxic cerebral anoxia. *J Hyperbaric Med* 1987; 2: 63-67
- 12 Finkel E. Stem cells in brain have regenerative potential. *Lancet* 1996; 347: 751
- 13 Staines WA, Craig J, et al. Retinoic acid treated P19 embryonal carcinoma cells differentiate into oligodendrocytes capable of myelination. *Neuroscience* 1996; 71: 845-853
- 14 Neubauer RA. The effect of hyperbaric oxygen in prolonged coma. Possible identification of marginally functioning brain zones. *Medicina Subacquea ed Iperbarica* 1985; 5: 75-79
- 15 Nudo RJ, Wise BM, SiFuentes F, Milliken GW. Neural substrates for the effects of rehabilitative training on motor recovery after ischemic infarct. *Science* 1996; 272: 1791-1794